

Situs Inversus Totalis in a Five-month-old Male Child Presenting with Cough: Diagnostic Clinical Images

SAYALI SANJAY BORSE¹, RENU B RATHI²

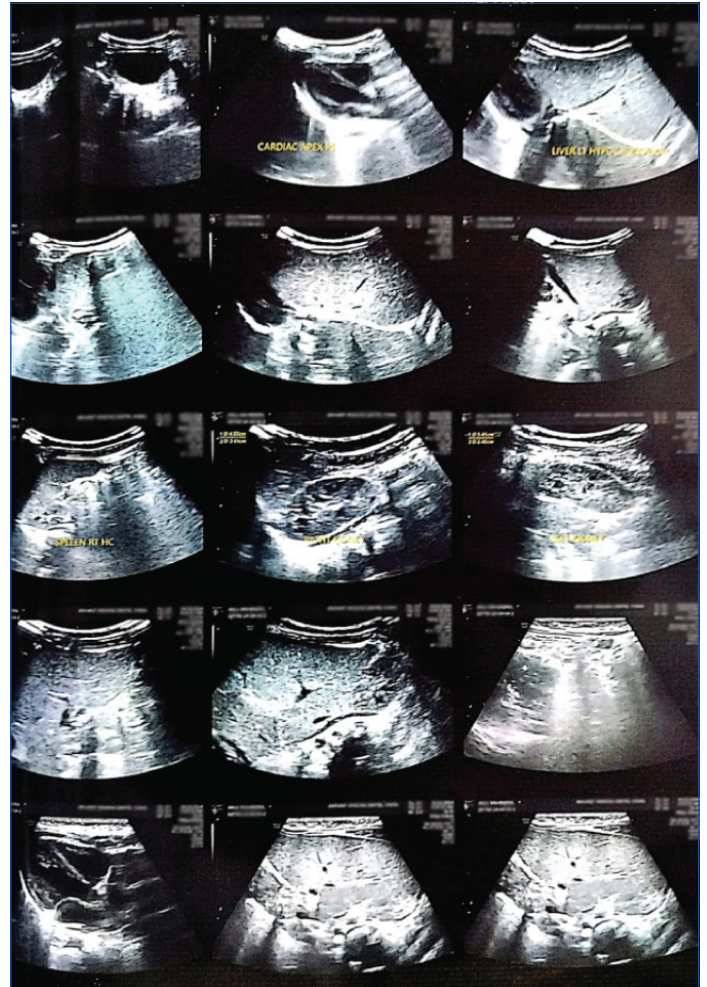
(CC) BY-NC-ND

Keywords: Dextrocardia, Left-right asymmetry, Mirror image transposition, Transposition of thoraco-abdominal organs

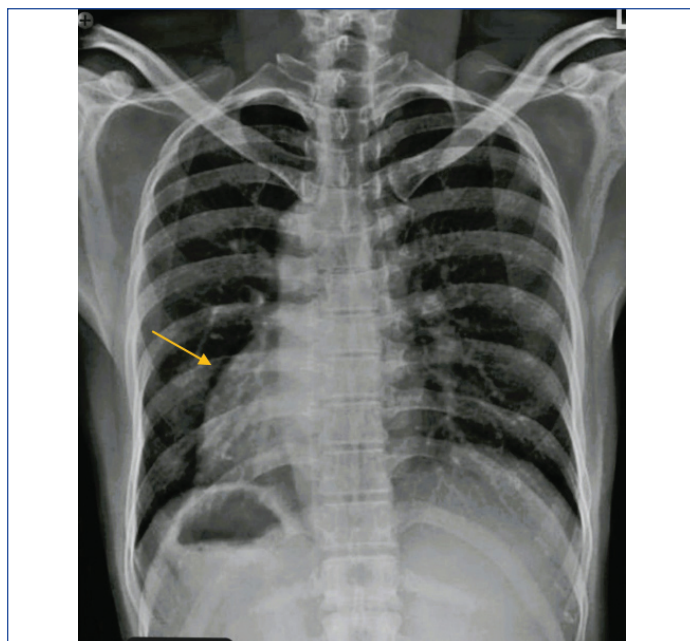
A five-month-old male child was brought by his parents to the Paediatric Outpatient Department, MGACH and RC with complaints of a persistent cough for a week. The cough was non productive and associated with mild fever. There was no significant past history of Inpatient Department admissions or any surgical procedures. The infant was born to a primiparous mother at full term via normal delivery. There was no significant family history of diabetes mellitus, hypertension, or known cases of any serious illness in close relatives.

A detailed head-to-toe examination of the child was performed, with particular focus on the respiratory system. Upon inspection, no scars or congenital anomalies were noticed. The child had an increased respiratory rate with mild subcostal retractions on both sides. On palpation, no thrills, lymphadenopathy, or organomegaly were found. Percussion did not reveal any significant abnormalities. Bilateral chest auscultation revealed decreased air entry in the left lung field, with slight wheezing heard on both sides. The patient was thoroughly examined for any abnormalities. As the child presented with bilateral wheezing, pneumonia was suspected, and a chest X-ray was advised.

The chest X-ray revealed no signs of pneumonia but showed that the apex of the heart was on the right-side instead of the left-side, as well as, a right-sided gastric bubble, suggestive of dextrocardia or complete situs inversus [Table/Fig-1]. Further evaluation with abdominal ultrasound confirmed dextrocardia, indicating the presence of the liver in the left hypochondrium, while the spleen was in the right hypochondrium, and other abdominal organs were in a mirror-image orientation [Table/Fig-2].



[Table/Fig-2]: Abdominal ultrasound showing dextrocardia, presence of liver in left hypochondrium, spleen in right hypochondrium and other abdominal organs in mirror-image orientation.



[Table/Fig-1]: Image of chest X-ray showing dextrocardia.

Differential diagnosis of situs inversus include situs inversus incompletes and situs inversus partialis, where there is a transposition of abdominal organs only, while the heart is in its normal position.

The patient was treated with an antihistaminic-antitussive (Solvin Cold AF, 0.6 mL three times a day for five days), an antipyretic (Calpol drops 100 mg/mL, 0.7-0.8 mL only if fever is present), and a course of antibiotics (Azee 100 mg/5 mL, 2.5 mL once a day, preferably in the morning, for three days). The parents were counselled regarding their baby's condition, including the unusual finding of situs inversus totalis. Detailed explanations were provided about the condition and the potential diagnostic challenges and medical procedural risks related to such an anatomical anomaly. They were advised to present the diagnostic records showing situs inversus totalis to all healthcare practitioners during any visits or whenever the baby presents with any medical ailments.

Situs inversus totalis is a rare condition characterised by the transposition of the major visceral organs. It is associated with a condition called mirror-image dextrocardia, where the heart is positioned on the right-side of the chest instead of the left. It is also characterised by the transposition of abdominal viscera, such as the spleen and stomach in the right hypochondrium while the liver is positioned in the left hypochondrium [1]. Situs inversus totalis is estimated to occur in approximately 1 in 10,000 to 1 in 20,000 births [2].

The exact cause of situs inversus totalis is not fully understood, but it is believed to result from disruptions in the normal process of embryonic development during the early foetal developmental stage when the organs form and migrate to their respective positions, leading to a complete reversal or mirror-image positioning of the major visceral organs [3]. While the precise genetic mechanisms responsible for it are not completely elucidated, several genetic factors, including mutations in genes, can play a role [4]. In some cases, situs inversus totalis may be inherited in an autosomal recessive manner [5]. However, the exact cause of situs inversus totalis remains the subject of ongoing research.

In most cases, situs inversus totalis does not significantly impact a person's quality of life, as long as, there are no associated health problems. Many individuals with this condition lead normal, healthy lives [6]. However, it can lead to diagnostic challenges, especially in cases where associated medical conditions present with symptoms related to abdominal and thoracic viscera. For example, when examining a patient for chest pain or abdominal pain, practitioners always keep normal anatomy in mind, which can alter the diagnosis in such rare cases of reversed anatomy. Similarly, when cardioversion is considered, the location of the application of patches differs in these cases. An altered pattern in Electrocardiogram (ECG) due to such anatomical reversal is normal when practitioners take this possibility into account. Additionally,

surgical or other medical procedures may need to be adjusted, considering the reversed anatomy.

CONCLUSION(S)

The present case underscores the importance of maintaining a high index of suspicion for rare anatomical variations, such as situs inversus totalis, especially in the evaluation of paediatric patients. Early recognition of such anomalies can guide appropriate diagnostic and therapeutic interventions, leading to improved patient outcomes. Additionally, detailed embryonic and genetic studies may provide valuable insights into human embryonic development and the complex genetic factors that govern organ formation and placement.

Acknowledgement

The authors would like to thank Dr. Chandrashekhar Patil (MBBS, MD, Paediatrics) and Dr. Sneha Patil (BAMS, DGO) for sharing valuable insights in the present case report.

REFERENCES

- [1] Rinkel M, Prineas R, Sarma DR. Situs inversus totalis: Clinical implications, challenges, and management. *Journal of Investigative Medicine High Impact Case Reports*. 2020.
- [2] Barber AT, Shapiro AJ, Davis SD, Ferkol TW, Atkinson JJ, Sagel SD, et al. Laterality defects in primary ciliary dyskinesia: Relationship to ultrastructural defect or genotype. *Ann Am Thorac Soc*. 2023;20(3):397-405. Doi: 10.1513/AnnalsATS.202206-487OC. PMID: 36342963; PMCID: PMC9993158.
- [3] Schoenwolf GC. *Larsen's Human Embryology*. Churchill Livingstone; 2009.
- [4] Li AH, Hanchard NA, Azamian M, D'Alessandro LCA, Coban-Akdemir Z, Lopez KN, et al. Genetic architecture of laterality defects revealed by whole exome sequencing. *Eur J Hum Genet*. 2019;27(4):563-73. Doi: 10.1038/s41431-018-0307-z. Epub 2019 Jan 8. PMID: 30622330; PMCID: PMC6460585.
- [5] Nussbaum RL, McInnes RR, Willard HF, Hamosh A, Thompson JS, Thompson MW. *Thompson & Thompson genetics in medicine*. 8th ed. Philadelphia, Pa: Elsevier/Saunders; 2016.
- [6] Jennings B, Thalange N, Willis G, Divan A. *Genetics in medicine*. Oxford, United Kingdom: Oxford University Press; 2020.

PARTICULARS OF CONTRIBUTORS:

1. Postgraduate Scholar, Department of Kaumarbhritya-Balrog, Mahatma Gandhi Ayurved College, DMIHER, Salod, Wardha, Maharashtra, India.
2. Professor and Head, Department of Kaumarbhritya-Balrog, Mahatma Gandhi Ayurved College, DMIHER, Salod, Wardha, Maharashtra, India.

NAME, ADDRESS, E-MAIL ID OF THE CORRESPONDING AUTHOR:

Dr. Sayali Sanjay Borse,
Postgraduate Scholar, Department of Kaumarbhritya-Balrog, Mahatma Gandhi Ayurved College Hospital and Research Centre, Datta Meghe Institute of Higher Education and Research, Salod (Hirapur), Wardha-442001, Maharashtra, India.
E-mail: borsesayali2@gmail.com

AUTHOR DECLARATION:

- Financial or Other Competing Interests: None
- Was informed consent obtained from the subjects involved in the study? Yes
- For any images presented appropriate consent has been obtained from the subjects. Yes

PLAGIARISM CHECKING METHODS: [Jain H et al.]

- Plagiarism X-checker: Jun 07, 2024
- Manual Googling: Jul 04, 2024
- iThenticate Software: Aug 22, 2024 (4%)

ETYMOLOGY: Author Origin

EMENDATIONS: 6

Date of Submission: **Jun 07, 2024**

Date of Peer Review: **Jun 29, 2024**

Date of Acceptance: **Aug 23, 2024**

Date of Publishing: **Nov 01, 2024**